

## Liver Fat Quantification Using MRI for Assessment of NAFLD/NASH

### Applications in Clinical Studies

Antaros Medical and ProSciento scientists have conducted many studies assessing liver lipid and glycogen homeostasis with interventions such as diet,<sup>1,2</sup> surgery,<sup>3,4</sup> as well as pharmaceutical interventions, including SGLT-2, GLP-1, and ARB.<sup>4-8</sup> For these studies, a consistent and precise quantification of liver fat is essential, especially when assessing efficacy and safety endpoints for new therapies for metabolic diseases such as type 2 diabetes mellitus, insulin resistance, obesity and NAFLD/NASH.

### High Precision Measurement

Magnetic Resonance Imaging (MRI) based methods that allow collection of fat and water specific signals are considered the most accurate non-invasive assessments of liver fat. Ultrasonography (US) and Computed Tomography (CT) measure liver fat using indirect properties. Moreover, MRI and Magnetic Resonance Spectroscopy (MRS) can both be utilized. MRI uses a model of the water and lipid signal and allows coverage of the entire liver and high spatial resolution, while MRS provides high spectral resolution from a few voxels. The MRI-based methods with full liver coverage and high spatial resolution allow specific analysis of the liver parenchyma, which is of importance for precision as it avoids signals from large vessels and bile ducts. Total method precision using repeated imaging (test-retest) and analysis in ten healthy volunteers is 0.1 percentage points (mean of the ten standard deviations). Antaros Medical also quantifies liver volume in all studies to allow assessment of changes in the non-lipid component (e.g. glycogen) of the liver. This allows estimation of total liver fat content in addition to the liver fat concentration.

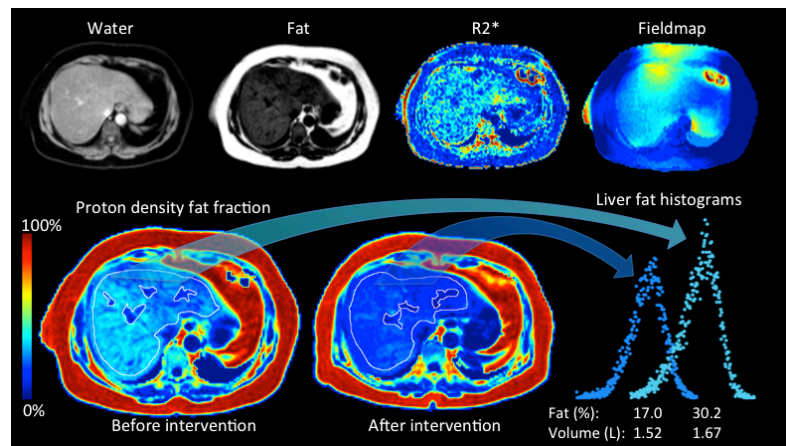



Figure: First row illustrates the collected and reconstructed image data from each MRI scan. The second row exemplifies fat fraction images before and after treatment with illustrations of sampled liver tissue regions and the extracted statistics (histograms) from the liver volume.

### Tolerability and Scanner Compatibility

The imaging protocols that Antaros Medical uses for the liver fat measurement only require a single breath hold, which is well tolerated by patients. We previously installed the protocols on all major clinical MRI vendors and field strengths, allowing maximum MRI site compatibility and subject inclusion in multi-center trials.

### Subjects and Preparation

Subjects are always screened for standard contraindications for MRI. Fasted state (>4h) and standardized time of the day is preferred to minimize variability.



## Procedure – Data Collection

Body coil or surface coils are used depending on the MRI system. The MRI protocol is a Proton Density Fat Fraction (PDFF) technique utilizing a spoiled 3D 6-echo gradient echo in the axial plane covering the entire liver. Image data is coded, exported and uploaded together with a scan log to our core lab for quality control and analysis.

## Procedure – Image Analysis

Depending on the MRI system, we use built-in solutions (provided by the manufacturers) for water-fat image reconstruction or our own published reconstruction algorithm.<sup>9</sup> The methods apply multi-peak lipid spectral models and simultaneous quantification and correction for T2\*. In addition, special care is taken to reduce effects of phase errors (eddy currents).<sup>10,11</sup> The liver fat value is the median value of all voxels in the identified volume of interest, excluding vessels and bile ducts. Quality control is performed in all steps of the process.

## Advantages of Antaros Medical's Liver Fat Quantification Using MRI

- High precision due to whole liver coverage with high spatial resolution analysis avoiding vessels and ducts leading to improved probability of detecting significant drug effects
- Accurate liver volume assessment included as a proxy for potential drug-induced effects on glycogen
- Integration with other liver morphology and functional measurements, such as diffusion, elastography and gadoxetate imaging for multiparametric assessment of NAFLD/NASH, as well as measurements of body composition<sup>1-7</sup> avoiding additional investigations
- Already used in over 20 clinical studies with more than 3,000 PDFF assessments

### References

- 1 Rosqvist F, Iggman D, **Kullberg J**, Cedernaes J, Johansson HE, Larsson A **Johansson L**, **Ahlström H**, Amer P, Dahlman I, Risérus U. Overfeeding polyunsaturated and saturated fat causes distinct effects on liver and visceral fat accumulation in humans. *Diabetes* 2014; 63: 2356–2368.
- 2 Bjermo H, Iggman D, **Kullberg J**, Dahlman I, **Johansson L**, Persson L, Berglund J, Pulkki K, Basu S, Uusitupa M, Rudling M, Amer P, Cederholm T, **Ahlström H**, Risérus U. Effects of n-6 PUFAs compared with SFAs on liver fat, lipoproteins, and inflammation in abdominal obesity: A randomized controlled trial. *Am J Clin Nutr* 2012; 95:1003–1012.
- 3 Edholm D, **Kullberg J**, Karlsson FA, Haenni A, **Ahlström H**, Sundbom M. Changes in liver volume and body composition during 4 weeks of low calorie diet before laparoscopic gastric bypass. *Surg Obes Relat Dis* 2014; 11: 602–606.
- 4 **Kullberg J**, Sundbom M, Haenni A, Freden S, **Johansson L**, Börnert P Ahlström A, **Ahlström H**, Karlsson A.. Gastric bypass promotes more lipid mobilization than a similar weight loss induced by low-calorie diet. *J Obes* 2011; 2011. doi:10.1155/2011/959601.
- 5 Eriksson JW, Jansson PA, Carlberg B, Hägg A, Kurland L, Svensson MK, **Ahlström H**, Ström C, Lönn L, Ojbrandt K, **Johansson L**, Lind L. Hydrochlorothiazide, but not Candesartan, aggravates insulin resistance and causes visceral and hepatic fat accumulation: the mechanisms for the diabetes preventing effect of Candesartan (MEDICA) Study. *Hypertension*. 2008 Dec;52(6):1030-7
- 6 Bolinder J, Ljunggren Ö, **Kullberg J**, **Johansson L**, Wilding J, Langkilde AM, Sugg J, Parikh S. Effects of dapagliflozin on body weight, total fat mass, and regional adipose tissue distribution in patients with type 2 diabetes mellitus with inadequate glycemic control on metformin. *J Clin Endocrinol Metab*. 2012 Mar;97(3):1020-31
- 7 Lundkvist P, David Sjoström C, Amini S, Pereira MJ, Johnsson E, Eriksson JW. Dapagliflozin QD and exenatide QW dual therapy: a 24-week randomized, placebo-controlled, phase 2 study examining effects on bodyweight and prediabetes in obese nondiabetic adults. *Diabetes Obes Metab* 2016; 23: 23.
- 8 Oscarsson J, Lundkvist P, Jansson P-A, **Johansson L**, Kvarnström M, Moris L, Risérus U, Lind L, Eriksson J. Effects of dapagliflozin, a sodium-glucose co-transporter 2 inhibitor, and free omega-3 carboxylic acids on liver steatosis and hepatocyte damage biomarkers in Type 2 diabetes patients with non-alcoholic fatty liver disease. Poster AASLD 2017
- 9 Berglund J, **Kullberg J**. Three-dimensional water/fat separation and T2\* estimation based on whole-image optimization-Application in breath hold liver imaging at 1.5 T. *Magn Reson Med* 2012; 67: 1684–93.
- 10 Yu H, Shimakawa A, Hines CDG, McKenzie CA, Hamilton G, Sirlin CB et al. Combination of complex-based and magnitude-based multiecho water-fat separation for accurate quantification of fat-fraction. *Magn Reson Med* 2011; 66: 199–206.
- 11 Hernando D, Hines CDG, Yu H, Reeder SB. Addressing phase errors in fat-water imaging using a mixed magnitude/complex fitting method. *Magn Reson Med* 2012; 67: 638–644

### About ProSciento's CRI Fact Sheets

Each fact sheet describes a select technique from our wide scope of complex methodologies for metabolic clinical research. Contact us for fact sheets highlighting additional techniques.

### Contact ProSciento

Business Development and Scientific Services  
US and Canada toll free +1 (866) 245-5445  
International +1 (619) 419-2038  
bd@prosciento.com  
www.prosciento.com

### Contact Antaros Medical

Antaros Medical  
Uppsala & Gothenburg, Sweden  
International +46-708467733  
info@antarosmedical.com  
www.antarosmedical.com